J Clin Gastroenterol 1994;19(4):321–4.

©1994 Raven Press, Ltd., New York

Endoscopy

Christopher J. Gostout, Editor

Gastric Heterotopia in the Upper Esophagus (Inlet Patch) in Endoscopic Surveys in Northern China

Guo-Qing Wang, M.D., Sanford M. Dawsey, M.D., Mei-Hong Zhou, M.D., and Klaus J. Lewin, M.D., FRC Path.

Upper esophageal gastric heterotopia (inlet patch) has not been reported in endoscopic series from China. We describe the occurrence of endoscopically and histologically typical inlet patches in two endoscopic surveys of asymptomatic adults in northern China. Because rapid endoscopic protocols were used, the 0.3–0.4% prevalence of inlet patch in these surveys probably represents a minimum figure for adults in this population.

Key Words: Endoscopy—Esophagus—Heterotopic gastric mucosa—*Helicobacter pylori*—China.

Inlet patch is an endoscopic term for a focal area of gastric heterotopia located in the upper esophagus, within or just below the upper esophageal sphincter (1). This finding has been described in endoscopic and autopsy series from the United States, Europe, and Japan, but has not been reported from China. In two large endoscopic surveys of asymptomatic adults in northern China, we identified endoscopically and histologically typical inlet patches, allowing us to document this finding and estimate its endoscopic prevalence in these Chinese populations.

PATIENTS AND METHODS

Both endoscopic surveys were components of larger studies of esophageal and gastric cardia cancer in areas of northern China where these tumors are endemic.

The first survey was conducted in Linxian, Henan Province, in April and May, 1991. This survey was carried out at the end of the Linxian nutrition intervention trials, two multiyear vitamin/mineral interventions conducted collaboratively by the Cancer Institute of the Chinese Academy of Medical Sciences and the U.S. National Cancer Institute (2).

Endoscopy was performed on 878 adult subjects, including 414 men and 464 women with an average age of 56 and an age range of 36 to 74 (Table 1). The patients were given 5 ml 1% Dicaine to drink 2–5 min before endoscopy but were not otherwise sedated and were alert throughout the procedure. The entire esophagus and stomach were visually examined, photographs were made of focal lesions, and biopsies were taken from focal lesions and four standard sites (midesophagus, cardia at 12 o'clock, cardia at 6 o'clock, and gastric angulus).

The second endoscopic survey was conducted in Cixian, Hebei Province, in October and November, 1992. This survey was part of ongoing studies of screening techniques in this high-risk population. Endoscopy was performed on 1,441 adults, including 676 men and 765 women, with an average age of 51 and an age range of 30 to 71 (Table 1). The endoscopy protocol was similar to that used in the previous survey in Linxian.

In both surveys, all biopsies were fixed in 10% buffered formalin, embedded in paraffin, cut in 5-micron sections, and stained with hematoxylin and eosin. Inlet patch and gastric biopsies were also stained with a modified Giemsa stain to look for organisms morphologically consistent with *Helicobacter pylori*.

RESULTS

During the Linxian survey, four endoscopically typical inlet patches were found in three patients (Table 2), a prevalence of 0.34%. These patches were found just below the upper esophageal sphincter and had characteristic pink mucosa, which was well demarcated from the surrounding whitish squamous epithelium (Fig. 1). A biopsy was taken from one of these sites and showed the

Received September 15, 1993. Sent for revision December 13, 1993. Accepted April 1, 1994.

From the Department of Chest Surgery (G.Q.W., M.H.Z.), Cancer Hospital of the Chinese Academy of Medical Sciences, Beijing, People's Republic of China; the Cancer Prevention Studies Branch (S.M.D.), National Cancer Institute, Bethesda, Maryland; and the Department of Pathology (K.J.L.), UCLA Center for the Health Sciences, Los Angeles, California, U.S.A.

Address correspondence and reprint requests to Dr. G.-Q. Wang, Department of Chest Surgery, Cancer Institute, Chinese Academy of Medical Sciences, P.O. Box 2258, Beijing 100021, People's Republic of China.

TABLE 1. *Occurrence of upper esophageal gastric heterotopia (inlet patch) in endoscopic surveys from Northern China*

Endoscopic survey	Number of subjects	Age range (mean)	Gender (% male)	Subjects with inlet patch	
				Number	Prevalence (%)
Linxian, 1991	878	36–74 (56)	47	3	0.34
Cixian, 1992	1,441	30–71 (51)	47	6	0.42

typical features of gastric heterotopia of cardiac–fundic type, a gastric-type columnar surface epithelium overlying mucous glands containing occasional parietal cells (Fig. 2). None of the three patients had any gastrointestinal symptoms. In two patients, all of the esophageal and gastric biopsies taken during endoscopy were histologically normal. In the third, the standard biopsy from the angulus showed intestinal metaplasia. No *Helicobacter*-like organisms were found in the biopsied inlet patch or in any of the standard-site gastric biopsies.

In the Cixian survey, eight typical inlet patches were identified in six patients (Table 2), a prevalence of 0.42%. None of the patients was symptomatic. Biopsies of three patches showed normal cardiac–fundic mucosa, and two other patches showed similar mucosa with mild infiltrates of chronic inflammatory cells. None of the patches showed *Helicobacter*-like organisms. In one patient, biopsies from a 7 × 3 cm erosion 8 cm below the inlet patch showed severe squamous dysplasia. No other patients had endoscopically visible abnormalities other than the inlet patches. Standard-site biopsies showed acute inflammation in the midesophagus in one patient, superficial chronic active gastritis in the cardia in two patients, and superficial chronic gastritis in the cardia in one patient. Organisms consistent with *Helicobacter pylori* were found in the two cardia biopsies showing chronic active gastritis but were not present in the other gastric biopsies.

DISCUSSION

Gastric heterotopia in the upper esophagus is thought to represent a remnant of gastric mucosa left behind during the descent of the stomach in the first 2 months of embryologic development (3–6). In most cases, it is an incidental endoscopic finding, as it was in all patients in this series. The clinical significance of this heterotopia lies in its ability to secrete acid (4,7,8), which in some cases can cause peptic injury and a burning sensation (9), dysphagia (7,9,10), stricture (10), or perforation with fistula formation (11). Rare cases of adenocarcinoma arising in inlet patch mucosa have also been reported (12,13).

The prevalence of an inlet patch has been reported as 0.1–10.0% in endoscopic series of adults from the United States, Europe, and Japan (4,6–

TABLE 2. *Patient characteristics and description of inlet patches*

Patient number	Endoscopic survey	Age	Gender	Description of inlet patches				Worst biopsy diagnosis[b]
				Number	Location[a]	Size	Biopsy findings	
1	Linxian	58	M	1	17–19 cm	1.5 × 1.0 cm	No biopsy taken	Normal mucosa
2	Linxian	55	F	2	15 cm	1.0 × 0.8 cm 0.8 × 0.5 cm	Normal cardiac–fundic mucosa No biopsy taken	Normal mucosa
3	Linxian	66	F	1	20 cm	0.8 × 0.6 cm	No biopsy taken	Intestinal metaplasia in the angulus
4	Cixian	44	F	1	15–16 cm	1.5 × 1.0 cm	No biopsy taken	Chronic active gastritis[c] in the cardia
5	Cixian	60	F	2	15–17 cm	2.0 × 1.0 cm 1.0 × 0.8 cm	Normal cardiac–fundic mucosa No biopsy taken	Normal mucosa
6	Cixian	61	F	2	16–17 cm	1.5 × 1.0 cm 0.8 × 0.8 cm	Normal cardiac–fundic mucosa No biopsy taken	Severe squamous dysplasia at 25–32 cm[a]
7	Cixian	59	M	1	19 cm	1.0 × 0.8 cm	Normal cardiac–fundic mucosa	Acute esophagitis at 26 cm[a]
8	Cixian	46	M	1	18 cm	1.5 × 1.0 cm	Cardiac–fundic mucosa with mild chronic inflammation	Chronic active gastritis[c] in the cardia
9	Cixian	54	M	1	17 cm	1.0 × 0.8 cm	Cardiac–fundic mucosa with mild chronic inflammation	Chronic gastritis in the cardia

[a]Location in centimeters from the incisor teeth.
[b]Worst esophageal or gastric biopsy diagnosis from the endoscopic examination.
[c]Associated with *Helicobacter*-like organisms.

9,14–17). Prevalences reported in autopsy studies have also varied widely, probably because of differences in study techniques. A careful autopsy study of 300 children in Britain found a 10% prevalence of macroscopically evident patches and a 21% prevalence of microscopic gastric-type mucosa in the upper esophagus (18). At least two autopsy studies of children reported a decrease in the prevalence of such mucosa with age (3,18). We are unaware of previous reports of upper esophageal gastric heterotopia from China.

The endoscopic surveys in Linxian and Cixian were components of larger studies of esophageal/gastric cardia cancer in Chinese populations, which have some of the highest rates of these tumors in the world (19). In both surveys, nearly all of the patients were asymptomatic, and endoscopy was performed for research and general surveillance purposes rather than for specific clinical indications. The patients were not sedated, so the examinations were rapid, and the primary focus was the identification of early neoplastic lesions. No special attention was given to examining the mucosa within or just below the upper sphincter. Still, foci of upper esophageal gastric heterotopia were identified that were endoscopically and histologically similar to those previously reported from other countries.

The prevalence rates of endoscopically identified inlet patch were consistent in the Linxian and Cixian surveys. These rates were lower than the prevalence rates reported in most other series, probably because of differences in endoscopic methods. It is well known that inlet patches are easily overlooked unless special attention is paid to examining the upper esophagus (4,6,16), and the endoscopic series reporting the highest prevalences took special care in this regard (4,6,14). In our rapid procedures, we probably noted only the largest and most obvious examples, so our findings must represent minimum figures for adults in these populations. Studies with sedation and a protocol designed to look for these foci would probably yield a higher and more accurate estimate of the true prevalence of this finding in China.

FIG. 1. Endoscopic appearance of the inlet patch in Patient 1. The pink mucosa of the patch is sharply demarcated from the adjacent squamous epithelium.

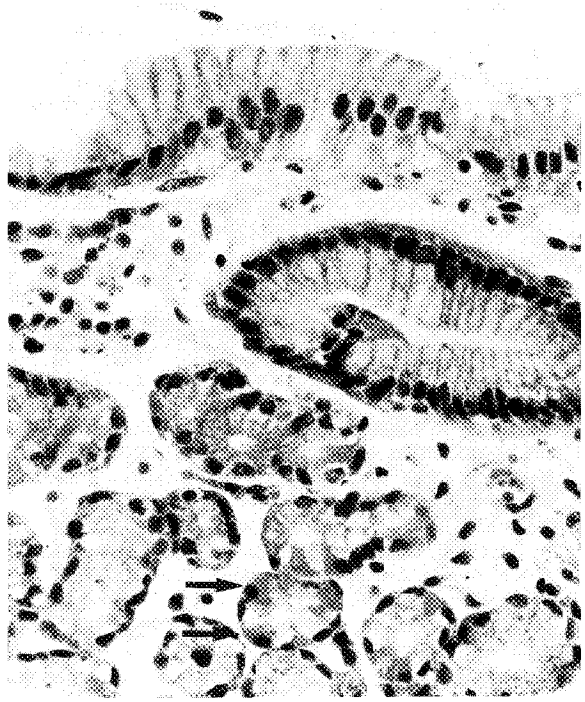

FIG. 2. Histologic appearance of an inlet patch in Patient 2, showing gastric-type columnar surface epithelium overlying mucous glands containing occasional parietal cells (arrows).

Recent reports from Europe and the United States have described *Helicobacter pylori*-like organisms in 5–19% of inlet patches (20,21). In these studies, inlet patch colonization was always associated with concurrent gastric infection. Finding *Helicobacter* in inlet patch mucosa appears to be another manifestation of this organism's ability to colonize foci of gastric metaplasia or heterotopia throughout the gastrointestinal tract (22–25). In our surveys, we found no *Helicobacter*-like organisms in the six inlet patches that were microscopically examined, but only one of these patients had a concurrent gastric *Helicobacter* infection, so the absence of inlet patch colonization was not surprising.

Acknowledgment: We thank Dr. Wilfred M. Weinstein of the Department of Medicine, UCLA, for his advice and assistance during the Linxian endoscopic survey.

REFERENCES

1. Lewin KJ, Riddell RH, Weinstein WM. Normal structures, developmental abnormalities, and miscellaneous disorders. In: Lewin KJ, Riddell RH, Weinstein WM, eds. *Gastrointestinal pathology and its clinical implications.* Vol. 1. New York: Igaku-Shoin, 1992:385–6.
2. Li B, Taylor PR, Li JY, et al. Linxian Nutrition Intervention Trials: design, methods, participant characteristics, and compliance. *Ann Epidemiol* 1993;3:577–85.

3. Rector LE, Connerly ML. Aberrant mucosa in the esophagus in infants and in children. *Arch Pathol* 1941; 31:285–94.
4. Jabbari M, Goresky CA, Lough J, Yaffe C, Daly D, Cote C. The inlet patch: heterotopic gastric mucosa in the upper esophagus. *Gastroenterology* 1985;89:352–6.
5. Feurle GE, Helmstaedter V, Buehring A, Bettendorf U, Eckardt VF. Distinct immunohistochemical findings in columnar epithelium of esophageal inlet patch and of Barrett's esophagus. *Dig Dis Sci* 1990;35:86–92.
6. Borhan-Manesh F, Farnum JB. Incidence of heterotopic gastric mucosa in the upper oesophagus. *Gut* 1991;32: 968–72.
7. Hamilton JW, Thune RG, Morrissey JF. Symptomatic ectopic gastric epithelium of the cervical esophagus: demonstration of acid production with Congo red. *Dig Dis Sci* 1986;31:337–42.
8. Nakajima H, Munakata A, Sasaki Y, Yoshida Y. pH profile of esophagus in patients with inlet patch of heterotopic gastric mucosa after tetragastrin stimulation: an endoscopic approach. *Dig Dis Sci* 1993;38:1915–19.
9. Shah KK, DeRidder PH, Shah KK. Ectopic gastric mucosa in proximal esophagus: its clinical significance and hormonal profile. *J Clin Gastroenterol* 1986;8:509–13.
10. Steadman C, Kerlin P, Teague C, Stephenson P. High esophageal stricture: a complication of "inlet patch" mucosa. *Gastroenterology* 1988;94:521–4.
11. Kohler B, Kohler G, Riemann JF. Spontaneous esophagotracheal fistula resulting from ulcer in heterotopic gastric mucosa. *Gastroenterology* 1988;95:828–30.
12. Christensen WN, Sternberg SS. Adenocarcinoma of the upper esophagus arising in ectopic gastric mucosa: two case reports and review of the literature. *Am J Surg Pathol* 1987;11:397–402.
13. Ishii K, Ota H, Nakayama J, et al. Adenocarcinoma of the cervical oesophagus arising from ectopic gastric mucosa. *Virchows Archiv A Pathol Anat* 1991;419:159–64.
14. Ottenjann R, Kunert H, Kuhner W, Seib HJ. Magenschleimhaut-inseln im zervikalen osophagus: Ihre potentielle pathogenetische bedeutung. *Dtsch Med Wochenschr* 1983;108:246–9.
15. Wang MMJ, Spear M, McGrew W. Heterotopic gastric mucosa of the esophagus. *South Med J* 1986;79:633–5.
16. Feller SC, Weaver GA. Heterotopic gastric mucosa in the upper esophagus. *Gastroenterology* 1986;90:257–8.
17. Truong LD, Strochlein JR, McKechnie JC. Gastric heterotopia of the proximal esophagus: a report of four cases detected by endoscopy and review of literature. *Am J Gastroenterol* 1986;81:1162–6.
18. Variend S, Howat AJ. Upper oesophageal gastric heterotopia: a prospective necropsy study in children. *J Clin Pathol* 1988;41:742–5.
19. Li MX, Li B, Li BR. Recent progress in research on esophageal cancer in China. *Adv Cancer Res* 1980;33:173–249.
20. Flejou JF, Potet F, Molas G, et al. *Campylobacter*-like organisms in heterotopic gastric mucosa of the upper oesophagus. *J Clin Pathol* 1990;43:961.
21. Borhan-Manesh F, Farnum JB. Study of *Helicobacter pylori* colonization of patches of heterotopic gastric mucosa (HGM) at the upper esophagus. *Dig Dis Sci* 1993; 38:142–6.
22. Paull G, Yardley JH. Gastric and esophageal *Campylobacter pylori* in patients with Barrett's esophagus. *Gastroenterology* 1988;95:216–8.
23. Caselli M, Trevisani L, Aleotti A, Bovolenta MR, Stabellini G. Gastric metaplasia in duodenal bulb and *Campylobacter*-like organisms in development of duodenal ulcer. *Dig Dis Sci* 1989;34:1374–8.
24. De Cothi GA, Newbold KM, O'Connor HJ. *Campylobacter*-like organisms and heterotopic gastric mucosa in Meckel's diverticula. *J Clin Pathol* 1989;42:132–4.
25. Dye KR, Marshall BJ, Frierson HF, Pambianco DJ, McCallum RW. *Campylobacter pylori* colonizing heterotopic gastric tissue in the rectum. *Am J Clin Pathol* 1990; 93:144–7.

Section Editor's Comments

It would appear that recognition of the heterotopic gastric inlet patch has surfaced among the mainland Chinese population. The inlet patch, suspected to be derived from persistent embryonic gastric mucosa, is probably present to keep the endoscopist in form, assuring that the esophagus is completely examined so that it may be identified. Its appearance is typical. The red ectopic gastric tissue may be millimeters in diameter, with flat discrete margins, or may appear in a completely circumferential fashion. It is most often encountered at or just below the upper esophageal sphincter. As the authors have pointed out, these patches can be associated with complications and symptoms such as ulceration and stricture formation (1). I remain ambivalent as to whether or not the uncomplicated patch can contribute to persistent cervical esophageal burning unless it is of sufficient size. Immunohistochemistry on biopsies has been reported to demonstrate endocrine cells, immunoreactive to antisera against glucagon, somatostatin, serotonin, and pancreatic polypeptide—findings that support an embryonic origin of the patch. The other reason for having these inlet patches exist is to house *Helicobacter pylori* and add to the unfolding drama surrounding this organism in the upper gut.

Christopher J. Gostout, M.D.
Rochester, Minnesota

REFERENCE

1. Wang G-Q, Dawsey SM, Zhou M-H, Lewin KJ. Gastric heterotopia in the upper esophagus (inlet patch) in endoscopic surveys in Northern China. *J Clin Gastroenterol* 1994;19:321–4.