Differences in Diagnostic Criteria for Esophageal Squamous Cell Carcinoma between Japanese and Western Pathologists

Ronald J. Schlemper, M.D., Ph.D.[1]
Sanford M. Dawsey, M.D.[2]
Masayuki Itabashi, M.D., Ph.D.[3]
Akinori Iwashita, M.D., Ph.D.[4]
Yo Kato, M.D., Ph.D.[5]
Morio Koike, M.D., Ph.D.[6]
Klaus J. Lewin, M.D.[7]
Robert H. Riddell, M.D.[8]
Tadakazu Shimoda, M.D., Ph.D.[9]
Pentti Sipponen, M.D., Ph.D.[10]
Manfred Stolte, M.D., Ph.D.[11]
Hidenobu Watanabe, M.D., Ph.D.[12]

[1] Department of Internal Medicine, Fukuoka University School of Medicine, Fukuoka, Japan.

[2] Cancer Prevention Studies Branch, National Cancer Institute, Bethesda, Maryland.

[3] Department of Pathology, Ibaraki Prefectural Central Hospital, Tomobe, Japan.

[4] Department of Pathology, Fukuoka University Chikushi Hospital, Fukuoka, Japan.

[5] Department of Pathology, Cancer Institute, Tokyo, Japan.

[6] Department of Pathology, Tokyo Metropolitan Komagome Hospital, Tokyo, Japan.

[7] Department of Pathology, University of California-Los Angeles Center for Health Sciences, Los Angeles, California.

[8] Department of Pathology, McMaster University Medical Centre, Hamilton, Ontario, Canada.

[9] Clinical Laboratory Division, National Cancer Center Hospital, Tokyo, Japan.

[10] Department of Pathology, Jorvi Hospital, Espoo, Finland.

[11] Institute of Pathology, Klinikum Bayreuth, Bayreuth, Germany.

[12] First Department of Pathology, Niigata University School of Medicine, Niigata, Japan.

BACKGROUND. Large discrepancies have been found between Western and Japanese pathologists in the diagnosis of adenoma/dysplasia versus carcinoma for gastric and colorectal glandular lesions. It is important to determine whether similar differences exist in the diagnosis of esophageal squamous lesions.

METHODS. Eleven expert gastrointestinal pathologists from Japan, North America, and Europe individually reviewed a set of microscopic slides containing 21 sections of biopsies and corresponding endoscopic mucosal resection specimens from Japanese patients with superficial esophageal squamous neoplastic lesions. The pathologists indicated the pathologic findings on which they based each diagnosis.

RESULTS. Invasion was the most important diagnostic criterion of carcinoma for the Western pathologists whereas nuclear and structural features were more important for the Japanese pathologists. For two sections showing low grade dysplasia according to most Western pathologists, the Japanese pathologists diagnosed suspected carcinoma in one case and definite carcinoma in the other. For nine sections with high grade dysplasia according to the Western pathologists, the Japanese pathologists diagnosed suspected carcinoma in two cases and definite carcinoma in seven cases. For six sections with suspected carcinoma according to most Western pathologists, the Japanese pathologists diagnosed suspected carcinoma in one case and definite carcinoma in five cases. Four sections showed definite carcinoma according to both the Western and Japanese pathologists. Thus, there was agreement among the Western and Japanese pathologists for only 5 of the 21 sections (kappa value, 0.04). However, when high grade dysplasia, noninvasive carcinoma, and suspected carcinoma were grouped together, the agreement was excellent (19 of the 21 sections; kappa value, 0.75).

CONCLUSIONS. In Japan, esophageal squamous cell carcinoma is diagnosed mainly based on nuclear criteria, even in cases judged to be noninvasive low grade dysplasia in the West. This difference in diagnostic practice may contribute to the relatively high incidence rate and good prognosis of superficial esophageal carcinoma in Japan. To improve the comparability of research data, the authors recommend that high grade dysplasia, noninvasive carcinoma, and suspected carci-

Presented in part as a presidential poster at the World Congresses of Gastroenterology, Austria, Vienna, September 7–11, 1998.

The authors thank Rikiya Fujita, M.D., Ph.D., and Hiroshi Takahashi, M.D., Ph.D., from the Department of Gastroenterology, Showa University Fujigaoka Hospital, Yokohama, Japan, for use of the histologic material and endoscopic films.

Address for reprints: Ronald J. Schlemper, M.D., Ph.D., Department of Internal Medicine, Fukuoka University School of Medicine, 7-45-1 Nanakuma, Jonan-ku, Fukuoka-shi 814-0180, Japan.

Received February 10, 1999; received August 5, 1999; accepted August 5, 1999.

© 2000 American Cancer Society

noma be grouped together into one category of "noninvasive high grade neoplasia." [See editorial on pages 969-70, this issue.] *Cancer* **2000;88:996–1006.**
© *2000 American Cancer Society.*

KEYWORDS: diagnosis, esophagus, squamous cell carcinoma, Japan, Western countries.

The mortality rate for esophageal squamous cell carcinoma is reported to be approximately 6 per 100.000 in Japan,[1] which is comparable to that in North America and much of Europe.[2] However, the overall 5-year survival rate of esophageal carcinoma is reported to be very different: 30–44% in Japan versus < 10% in Western countries.[3-6] Squamous cell carcinoma is the predominant histologic type of esophageal carcinoma in Japan and accounts for approximately 60% of esophageal carcinomas in North America and much of Europe.[4,6] Approximately 24–42% of all esophageal squamous cell carcinomas in Japan are diagnosed as "superficial carcinomas,"[3,7,8] which includes carcinomas limited to the mucosa or submucosa regardless of lymph node status, and approximately 50% of these are mucosal carcinomas,[3,7] for which the 5-year survival is nearly 100%.[9,10] In contrast, in Western countries the proportion of superficial carcinomas is ≤ 15% and that of mucosal carcinomas is < 7%.[6,11-13]

The relatively high incidence rate of superficial esophageal carcinoma in Japan, and the resulting good prognosis, have been attributed to the large number of routine endoscopies that are performed for nonspecific symptoms and to the widespread use of chromoscopic techniques (spraying the mucosa with iodine solution).[5,8,14,15] However, a different use of pathologic nomenclature also could be a contributing factor. Indeed, large differences have been found between Western and Japanese pathologists in the diagnosis of adenoma/dysplasia versus carcinoma for gastric and colorectal glandular lesions.[16,17] The aim of the current study was to investigate whether similar differences exist in the diagnosis of esophageal squamous lesions.

In Western countries, esophageal squamous cell carcinoma is diagnosed when neoplastic epithelium is observed to invade into the lamina propria of the mucosa or beyond.[2,4] The term "dysplasia" is used to indicate a noninvasive neoplastic lesion in which nuclear atypia (enlargement, pleomorphism, hyperchromasia), loss of normal cellular polarity, and abnormal tissue maturation are present in the lower half ("low grade") or in both halves ("high grade") of the squamous epithelium.[2,4,15] Full-thickness involvement of the epithelium is called "carcinoma in situ" by some but usually is included under high grade dysplasia.[15,18] The diagnostic criteria of esophageal carcinoma in Japan are less clear.[19-24] However, an accurate understanding of these criteria is essential for pathologists and clinicians to interpret correctly the results of Japanese cancer research.

We were under the impression that Japanese pathologists often render a diagnosis of squamous cell carcinoma for lesions that Western pathologists consider to be dysplasia.[4] To test this hypothesis, 11 expert gastrointestinal pathologists from North America, Europe, and Japan individually reviewed microscopic slides of early esophageal squamous neoplastic lesions. We then compared the diagnoses of the Japanese and Western pathologists and investigated the criteria used by both groups for the diagnosis of squamous cell carcinoma.

MATERIALS AND METHODS

The study included 11 pathologists who are all specialists in neoplasia of the gastrointestinal tract. Five were from Western countries and six were from Japan. The microscopic slides were from five consecutive Japanese patients who underwent endoscopic mucosal resection (EMR) for superficial esophageal squamous neoplastic lesions at the Department of Gastroenterology, Showa University Fujigaoka Hospital, Yokohama, Japan. The macroscopic appearances were of the slightly depressed type (0–IIc) in four patients and of the flat type (0–IIb) in one patient.[9,19] Of these lesions, 10 sections of biopsies and 11 sections of corresponding EMR specimens were selected by one of the authors (R.J.S.) for individual review. The pathologists were not told the relation between the biopsies and the EMR specimens. For intergroup comparisons, the most common diagnosis of each group was taken as the group's final diagnosis.

A list of pathologic findings that commonly are used as diagnostic criteria was prepared (Table 1). The pathologists were asked to fill in their diagnosis of each histologic section on a standardized form by choosing from the following diagnoses: definite carcinoma (subclassified by the depth of invasion), suspected carcinoma, high grade dysplasia, low grade dysplasia, indefinite for dysplasia, and reactive or regenerative epithelium. In addition, the pathologists

TABLE 1
Findings on Which the Histologic Diagnosis of an Esophageal Lesion Was Based

Invasion
1. No invasion
2. Questionable invasion into the lamina propria
3. Invasion into the lamina propria
4. Invasion into the muscularis mucosae
5. Invasion into the submucosa
Epithelial structure
6. Normal cellularity
7. Increased cellularity
8. Increase of undifferentiated (atypical) cells in the lower third of the epithelium
9. Increase of undifferentiated (atypical) cells in the lower two-thirds of the epithelium
10. Increase of undifferentiated (atypical) cells in the upper third of the epithelium as well
11. Increase of undifferentiated (atypical) cells involving the full thickness of the epithelium
12. Increase of undifferentiated (atypical) cells involving an indeterminate thickness of the epithelium
13. Preserved gradual differentiation toward the surface
14. Sharp border between lower undifferentiated layers and upper more differentiated layers
15. Scattered markedly enlarged and/or hyperchromatic nuclei in the upper two-thirds of the epithelium
16. Gradual lateral transition of atypical to normal epithelium
17. Sharp lateral border between atypical and normal epithelium
18. Dyskeratosis or single cell dyskeratosis
Nuclei
19. Nearly normal size, shape, and polarity
20. Homogeneous chromatin
21. Vesicular chromatin
22. Mild or moderate hyperchromatism
23. Marked hyperchromatism
24. Variable size and/or enlarged
25. Increased nuclear-cytoplasmic ratio
26. Irregular shape
27. Loss of polarity
28. Enlarged prominent nucleoli
29. Frequent and/or atypical mitotic figures
Cells
30. Inflammatory infiltrate in the epithelium
31. Poorly developed intercellular bridges

were asked to specify which three findings from Table 1 they judged to be the most important clues for the diagnosis of each section.

Statistical Analysis

The extent of agreement between the Western and Japanese pathologists was assessed by the simple kappa coefficient and its 95% confidence interval (95% CI) using the computer program "AGREE."[25] Kappa values < 0.4 represent poor agreement, values between 0.4–0.75 represent fair to good agreement, and values > 0.75 represent excellent agreement.

RESULTS

There were no major differences among the 6 Japanese pathologists in the diagnoses of the 21 sections (Table 2). They all made a diagnosis of suspected or definite carcinoma in 95–100% of the sections. However, there was a much larger distribution of diagnoses among the five Western pathologists. They diagnosed suspected or definite carcinoma in only 38–67% of the sections (average, 48%) (Table 2). When the most common opinion was taken as each group's final diagnosis, there was disagreement between the Western and Japanese pathologists in 16 of the 21 sections (Table 3).

In two biopsy sections, the Western pathologists diagnosed low grade dysplasia and the Japanese pathologists diagnosed suspected or definite carcinoma (Table 3) (Figs. 1C and 1D). The Western pathologists stressed the absence of invasion and the finding that the atypical cells with hyperchromatic nuclei and loss of polarity were restricted to the lower half of the epithelium, whereas the Japanese emphasized the nuclear features, such as the marked hyperchromatism, the variable and enlarged size, and the irregular shape of the nuclei.

In four biopsy and five EMR sections, the Western pathologists diagnosed high grade dysplasia and the Japanese pathologists diagnosed suspected or definite carcinoma (Table 3) (Figs. 1E, 1F, 2C, and 2D). For these different diagnoses, the Western and Japanese pathologists often indicated similar findings, such as hyperchromatic, variably sized, enlarged, and dyspolaric nuclei extending into the upper half of the epithelium. However, the Western pathologists also emphasized the absence of evident invasion. In contrast, the Japanese pathologists diagnosed malignancy without evident invasion based on the nuclear features mentioned earlier, irregular nuclear shape, enlarged prominent nucleoli, and structural criteria such as sharp lateral or horizontal borders between undifferentiated and more differentiated parts of the epithelium or the finding of single cell dyskeratosis.

In one biopsy section there was agreement regarding the diagnosis of suspected carcinoma, but in two other biopsies and three EMR sections the Western versus Japanese viewpoint was suspected versus definite carcinoma (Table 3) (Fig. 2E). The Western diagnosis of suspected carcinoma was based on questionable invasion into the lamina propria, whereas the Japanese diagnosis of definite carcinoma was based

TABLE 2
Distribution of Diagnoses of the Individual Pathologists, Classified According to Neoplastic Severity

	Western pathologists						Japanese pathologists						
Diagnosis	SD	KL	RR	PS	MS	Total	AI	MI	MK	YK	TS	HW	Total
Low grade dysplasia	3	2	5	9	0	19 (18%)	0	0	0	0	0	0	0 (0%)
High grade dysplasia	10	10	7	2	7	36 (34%)	0	1	0	1	0	0	2 (2%)
Suspected carcinoma	5	4	8	2	0	19 (18%)	1	1	3	5	7	0	17 (13%)
Definite carcinoma	3	5	1	8	14	31 (30%)	20	19	18	15	14	21	107 (85%)
Total	21	21	21	21	21	105 (100%)	21	21	21	21	21	21	126 (100%)

TABLE 3
Diagnoses and Most Important Findings Specified by Western and Japanese Pathologists in the 21 Sections of Esophageal Biopsy and Resection Specimens

	Western pathologists				Japanese pathologists			
	Biopsy		EMR		Biopsy		EMR	
Case no.	Diagnosis	Findings[a]	Diagnosis	Findings[a]	Diagnosis	Findings[a]	Diagnosis	Findings[a]
1	LGD	1, 23, 27	HGD	1, 11, 27	DCA	18, 23, 24	DCA	11, 17, 27
	HGD	11, 23, 24			DCA	11, 24, 27		
2	LGD	1, 8, 23	HGD	1, 23, 24	SCA	23, 24, 26	DCA	24, 27, 28
	HGD	9, 23, 24	HGD	1, 9, 23	SCA	23, 24, 26	DCA	14, 24, 28
	HGD	1, 9, 27	HGD	1, 24, 27	DCA	9, 14, 24	DCA	24, 27, 28
			HGD	1, 12, 24			DCA	24, 27, 28
3	HGD	1, 12, 27	SCA	2, 24, 27	SCA	7, 23, 27	DCA	17, 24, 27
	SCA	2, 11, 27	DCA	3, 24, 27	DCA	11, 24, 27	DCA	3, 11, 27
4	SCA	2, 8, 24	SCA	2, 24, 27	SCA	7, 23, 24	DCA	9, 24, 27
	SCA	2, 18, 24	SCA	2, 26, 27	DCA	11, 18, 24	DCA	2, 24, 27
5	DCA	3, 27, 28	DCA	3, 21, 28	DCA	11, 24, 27	DCA	11, 24, 27
			DCA	4, 27, 28			DCA	4, 11, 24

EMR: endoscopic mucosal resection; LGD: low grade dysplasia; HGD: high grade dysplasia; DCA: definite carcinoma, SCA: suspected carcinoma.
[a] Numbers relate to the diagnostic criteria listed in Table 1.

on the presence of the nuclear and structural findings described earlier.

In one biopsy and three EMR sections there was agreement regarding the diagnosis of definite carcinoma (Table 3) (Fig. 2F). All Western pathologists based this diagnosis on evident invasion into or beyond the lamina propria. Most, but not all, Japanese pathologists also mentioned the presence of invasion as an important finding. In the two patients diagnosed by both the Western and Japanese pathologists as having definite carcinoma in their EMR specimens, the Japanese pathologists had made this diagnosis already from the corresponding biopsies in both patients but the Western pathologists had made this diagnosis in only one patient (Table 3).

All 13 sections that were diagnosed as definite carcinoma by the Japanese pathologists and were given other diagnoses by the Western pathologists were subclassified as noninvasive carcinoma by the Japanese pathologists.

Overall, there was agreement between the Western and Japanese pathologists in only 5 of the 21 sections (Fig. 3A) (kappa coefficient, 0.04 [95% CI, -0.11–0.18]). Even when suspected and definite carcinomas were grouped together, there was agreement between the Western and Japanese diagnoses in only 10 of the 21 sections. However, when high grade dysplasia, noninvasive carcinoma, and suspected carcinoma were grouped together into 1 category of "noninvasive high grade neoplasia," there was excellent agreement, in 19 of the 21 sections (Fig. 3B) (kappa coefficient, 0.75 [95%CI, 0.41–1.00]).

DISCUSSION

This study confirms that Japanese pathologists often diagnose esophageal squamous cell carcinoma when

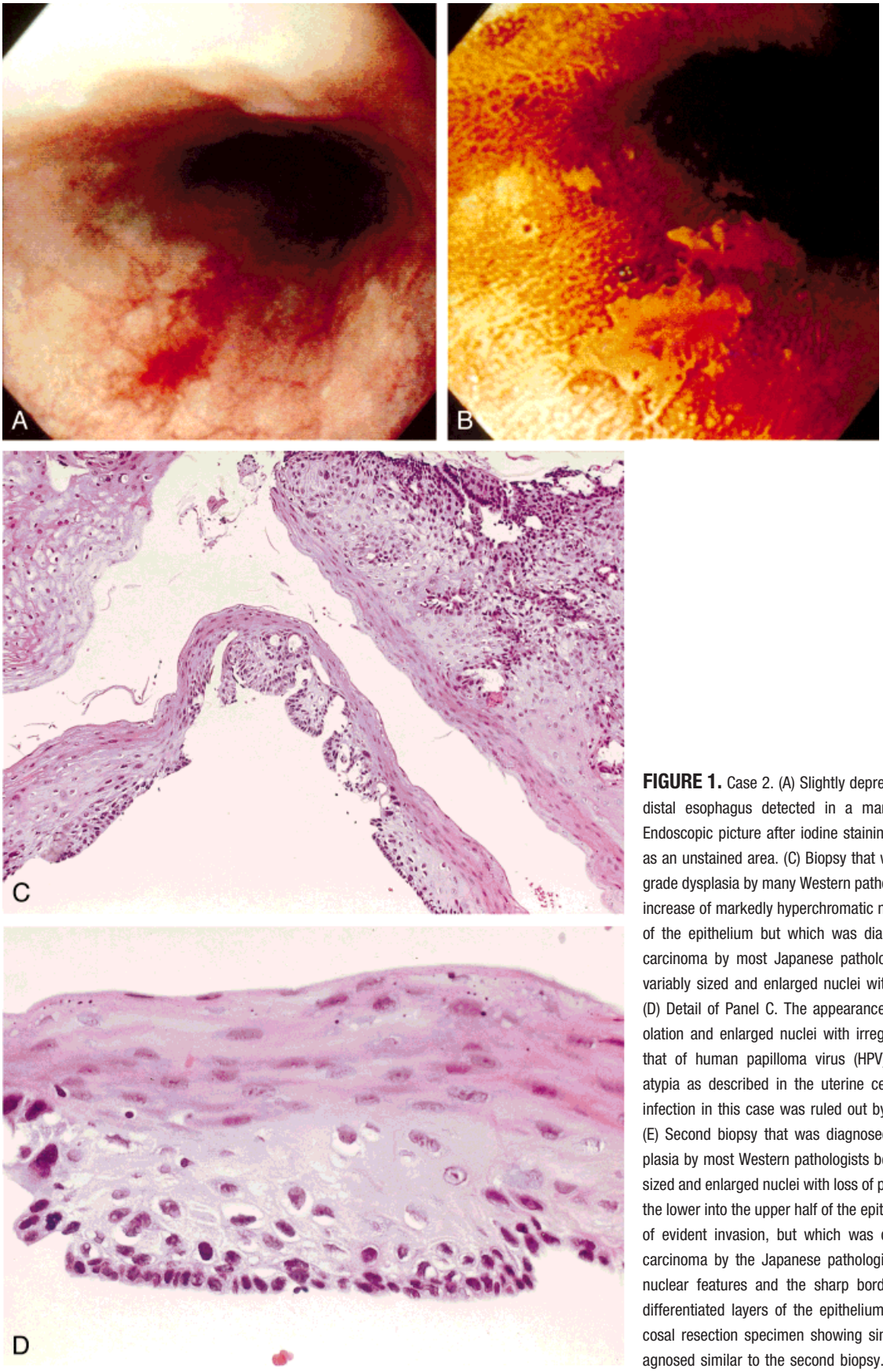

FIGURE 1. Case 2. (A) Slightly depressed red lesion in the distal esophagus detected in a man age 59 years. (B) Endoscopic picture after iodine staining, showing the lesion as an unstained area. (C) Biopsy that was diagnosed as low grade dysplasia by many Western pathologists because of an increase of markedly hyperchromatic nuclei in the lower half of the epithelium but which was diagnosed as suspected carcinoma by most Japanese pathologists because of the variably sized and enlarged nuclei with an irregular shape. (D) Detail of Panel C. The appearance of perinuclear vacuolation and enlarged nuclei with irregular contours mimics that of human papilloma virus (HPV)-induced koilocytotic atypia as described in the uterine cervix[26]; however, HPV infection in this case was ruled out by in situ hybridization. (E) Second biopsy that was diagnosed as high grade dysplasia by most Western pathologists because of the variably sized and enlarged nuclei with loss of polarity extending from the lower into the upper half of the epithelium in the absence of evident invasion, but which was diagnosed as definite carcinoma by the Japanese pathologists because of these nuclear features and the sharp border with upper, more differentiated layers of the epithelium. (F) Endoscopic mucosal resection specimen showing similar features and diagnosed similar to the second biopsy.

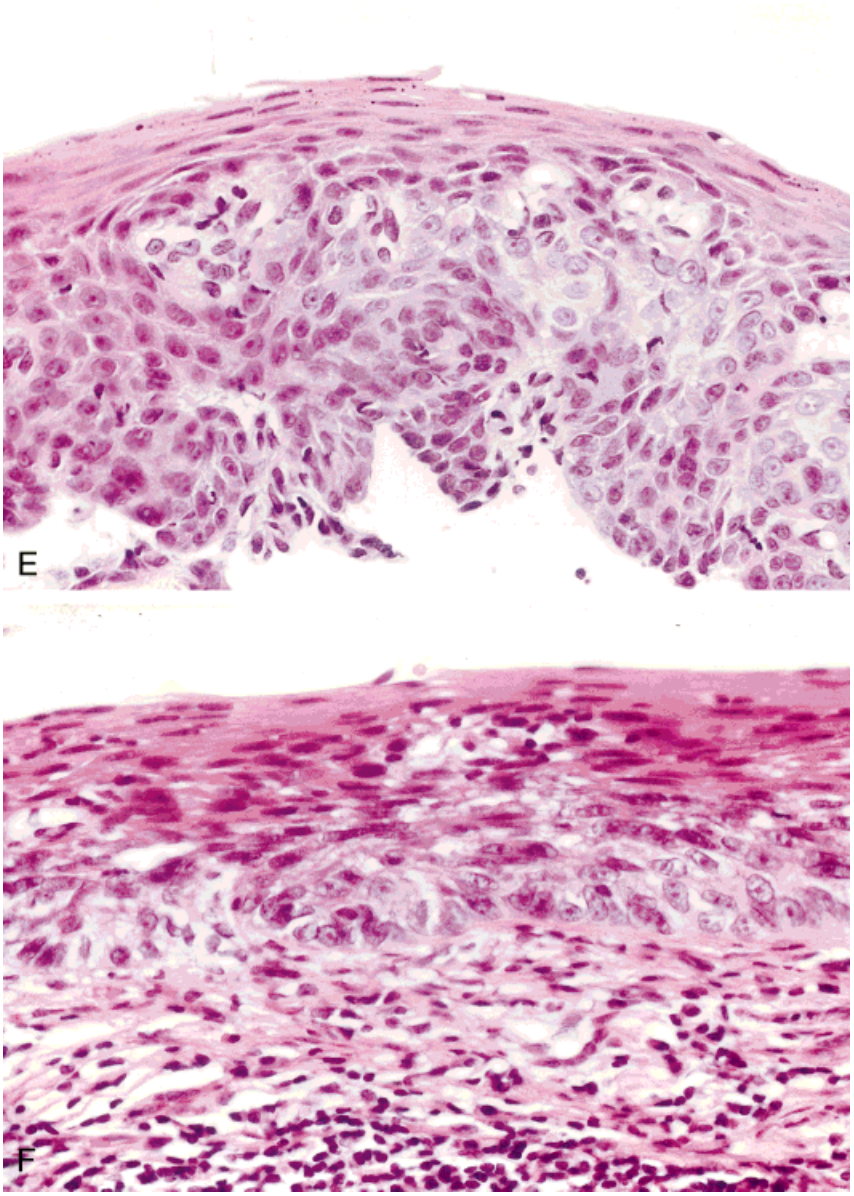

FIGURE 1. (*continued*)

Western pathologists use the term dysplasia to indicate the presence of a benign (noninvasive) neoplastic epithelial proliferation that may have the potential to become invasive. Whereas Western pathologists consider the presence of evident invasion into the lamina propria of the mucosa as a prerequisite for the diagnosis of esophageal carcinoma, Japanese pathologists do not require such invasion, and they base their diagnosis of carcinoma on nuclear features and changes in the epithelial structure. This diagnostic practice by Japanese pathologists results in few discrepancies between the diagnosis of a superficial biopsy specimen and that of the final resection specimen.[23,27]

These differences in diagnostic practice have important clinical implications. Previous studies have shown that noninvasive esophageal squamous neoplasia does not metastasize to lymph nodes or distant sites, but that lymph node metastases are found in 8–15% of mucosal carcinomas invading to the level of the muscularis mucosae and in 30–47% of carcinomas invading into the submucosa.[8-10,28] Clearly, accurate determination of the presence and depth of invasion is important, but this can be hindered by the sampling error of endoscopic biopsies, which may miss the presence of nearby invasion (as in the third case in the current study, in which the biopsy section in Figure 2C missed the invasive focus). According to the experi-

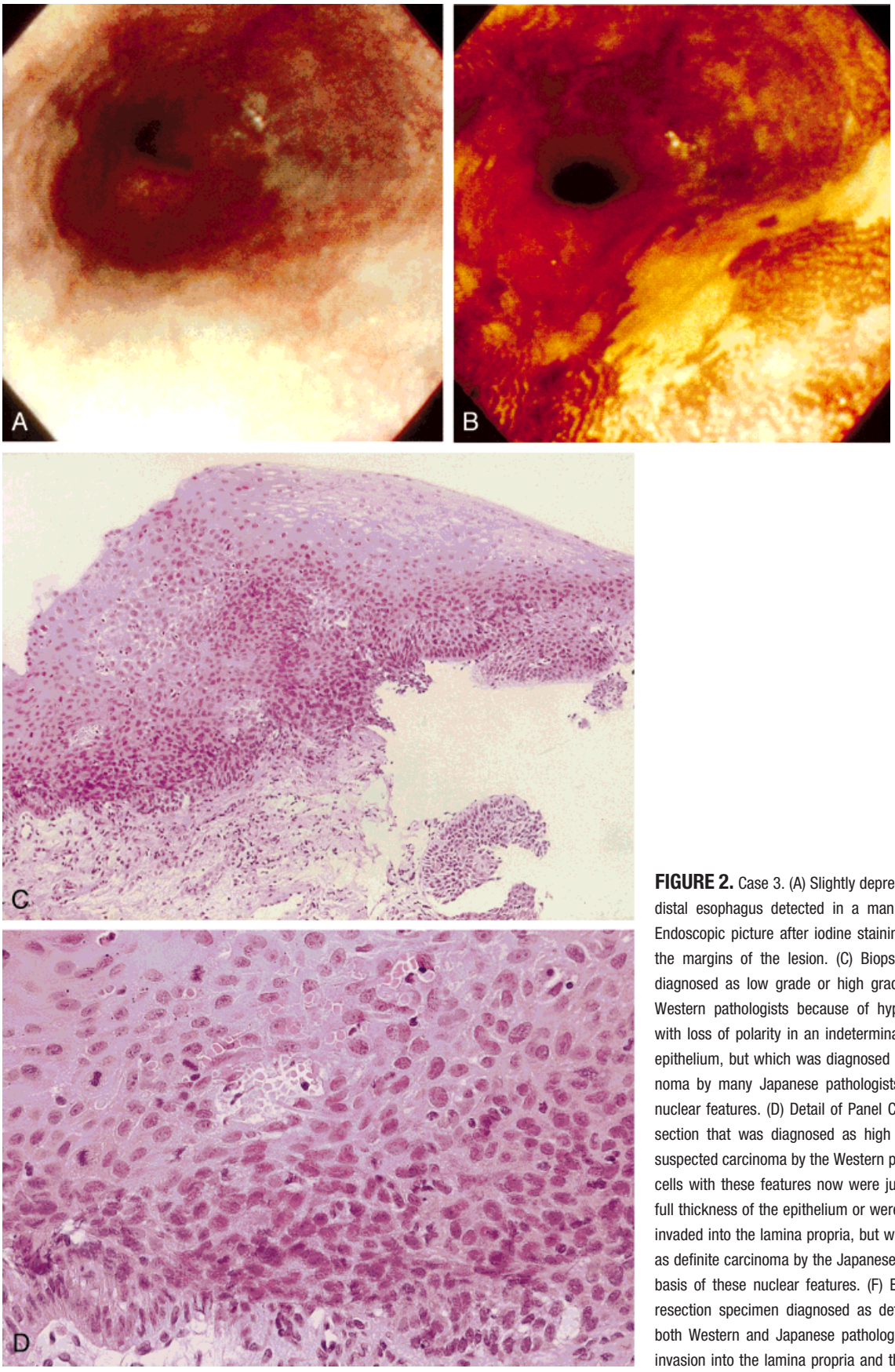

FIGURE 2. Case 3. (A) Slightly depressed red area in the distal esophagus detected in a man age 71 years. (B) Endoscopic picture after iodine staining, clearly revealing the margins of the lesion. (C) Biopsy section that was diagnosed as low grade or high grade dysplasia by the Western pathologists because of hyperchromatic nuclei with loss of polarity in an indeterminate thickness of the epithelium, but which was diagnosed as suspected carcinoma by many Japanese pathologists because of these nuclear features. (D) Detail of Panel C. (E) Second biopsy section that was diagnosed as high grade dysplasia or suspected carcinoma by the Western pathologists because cells with these features now were judged to involve the full thickness of the epithelium or were suspected to have invaded into the lamina propria, but which was diagnosed as definite carcinoma by the Japanese pathologists on the basis of these nuclear features. (F) Endoscopic mucosal resection specimen diagnosed as definite carcinoma by both Western and Japanese pathologists because of the invasion into the lamina propria and the nuclear features.

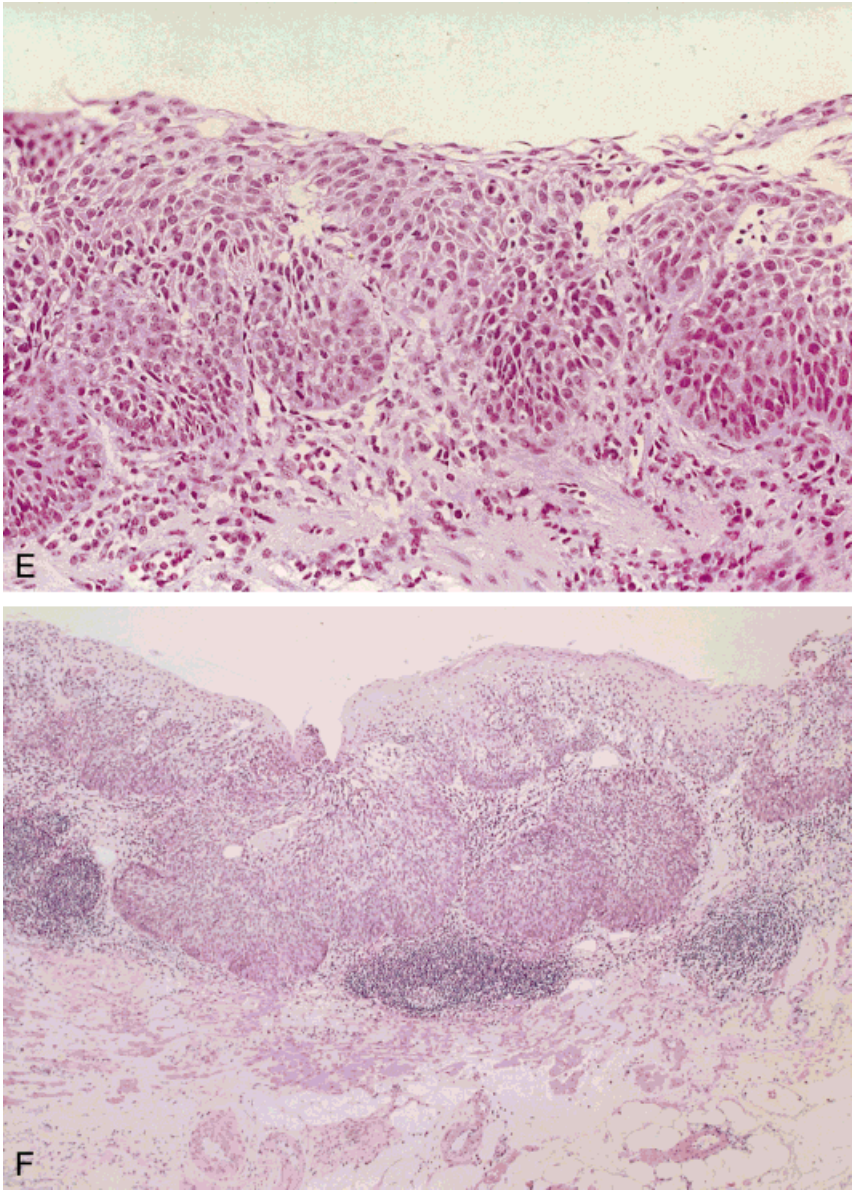

FIGURE 2. (*continued*)

ence of Japanese pathologists, the diagnosis of carcinoma from nuclear features in noninvasive biopsy specimens is necessary for the successful early detection and treatment of invasive squamous cell carcinoma. In contrast, Western pathologists prefer to restrict the diagnosis of carcinoma to lesions with demonstrable invasion, and they grade noninvasive neoplasia to give an estimate of the probability of concurrent or future invasive disease.[29] To our knowledge the possible negative consequences of diagnosing carcinoma in patients with noninvasive lesions have not been studied, but are mitigated in Japan by the availability of endoscopic mucosal resection, which has a low rate of complications.[3,28,30] This technique can be employed both diagnostically and therapeutically as an intermediate procedure between biopsy and esophagectomy, allowing microscopic evaluation of larger amounts of tissue and curative treatment of focal noninvasive and early invasive neoplasia.[1,3,7-9,14,23,28,30]

We found that in some cases Western pathologists diagnosed low grade dysplasia in a biopsy when Japanese pathologists diagnosed suspected or definite noninvasive carcinoma. In Western countries low grade dysplasia usually is dealt with by endoscopic follow-up. Because of possible sampling error, there are methodologic problems in determining the natural course of neoplastic lesions. Thus the Western

(A)

Western pathologists \ Japanese pathologists	L	H	S	D	Tot
L			1	1	2
H			2	7	9
S			1	5	6
D				4	4
Tot	0	0	4	17	21

Agreement: 5/21 = 24%

Kappa coefficient: 0.04
(95% CI: -0.11 - 0.18)

(B)

Western pathologists \ Japanese pathologists	C3	C4	C5	Tot
C3		2		2
C4		15		15
C5			4	4
Tot	0	17	4	21

Agreement: 19/21 = 90%

Kappa coefficient: 0.75
(95% CI: 0.41 - 1.00)

FIGURE 3. Extent of agreement between five Western and six Japanese pathologists; the diagnoses were based on (A) traditionally used classification systems and (B) the Vienna classification system. L: low grade dysplasia; H: high grade dysplasia; S: suspected carcinoma; D: definite carcinoma; Tot: total; C3: noninvasive low grade neoplasia; C4: noninvasive high grade neoplasia (high grade dysplasia plus noninvasive carcinoma plus suspected carcinoma); C5: invasive neoplasia; 95% CI: 95% confidence interval.

approach may lead to underdiagnosis and delayed treatment and the Japanese approach may lead to overdiagnosis and unnecessary treatment, both of which may lead to unnecessary patient morbidity and the unnecessary use of health care resources. However, questions regarding the desirability of different approaches cannot be addressed meaningfully by the limited data in the current study, in which the Japanese consensus diagnoses included only suspected or definite carcinoma. Evaluation of such questions would require prospective studies of a larger number of cases with a full spectrum of esophageal lesions.

In the majority of cases in the current study the differences in diagnoses could be attributed to the Western pathologists diagnosing high grade dysplasia when the Japanese pathologists diagnosed suspected or definite noninvasive carcinoma. Nearly all pathologists would recommend complete resection in cases of high grade dysplasia. In fact, there currently is the paradoxical situation that in the West more extensive therapy usually is advised for lesions that receive a milder diagnosis than in Japan: esophagectomy for "high grade dysplasia" in the West versus endoscopic resection for "mucosal carcinoma" in Japan. Many such intraepithelial neoplastic lesions actually may be missed during endoscopy if dye spraying with iodine solution is not performed,[4,8,14] and the option of endoscopic resection must be available to excise these lesions locally. Thus, from a therapeutic viewpoint, infrequent use of iodine spraying and a lack of experience with endoscopic mucosal resection in the West may be more of a problem than exactly how the lesions are named.

The differences in nomenclature revealed in this study also have major consequences for the interpretation of research, especially epidemiologic studies. Just as for early gastric and colorectal carcinomas,[16,17] the different diagnostic criteria may contribute to the relatively high incidence rate and good prognosis of superficial esophageal carcinoma in Japan when compared with Western countries, in addition to other contributory factors such as the more frequent use of endoscopic examinations and chromoscopic techniques.[5,8,15] Other clinical research also may suffer from the lack of comparability between data generated in Japanese and Western studies, leading to contradictory conclusions. For example, the use of iodine staining at endoscopy has been reported to improve the detection rate of esophageal squamous cell carcinoma only modestly in Western studies,[31] but remarkably well in Japanese studies.[14] This apparent discrepancy can be resolved when the "carcinomas" are stratified by invasion status. In both populations, iodine staining improves the detection rate of invasive squamous cell carcinomas only slightly, but it greatly improves the detection of noninvasive high grade squamous neoplasia.[4] Such studies emphasize the need for a worldwide consensus regarding the nomenclature of esophageal squamous neoplasia.

It is clear from the current study that the Western diagnosis of high grade squamous dysplasia is reasonably comparable to the Japanese diagnosis of squamous carcinoma without evident invasion. In addition, there is nearly complete agreement among Western and Japanese pathologists regarding the diagnosis of carcinoma with definite invasion. Indeed,

after stratifying the data by invasion status (by grouping high grade dysplasia, noninvasive carcinoma, and suspected carcinoma together into one category) the Western and Japanese diagnoses in the current study did not differ significantly (Fig. 3B). Such stratification by invasion status is natural because invasion is an indicator of metastatic potential and therefore of major prognostic significance, and it resulted in a remarkable increase in the diagnostic agreement in the cases in the current study (from 24% to 90% of the histologic sections reviewed).

Realizing the need for common worldwide terminology for early neoplastic lesions of the digestive tract, a group of 30 pathologists from 12 countries recently met in Vienna, Austria, and proposed a consensus classification, the Vienna classification for gastrointestinal epithelial neoplasia, to be used for lesions throughout the gastrointestinal tract.[32,33] In this classification, high grade dysplasia, noninvasive carcinoma, and suspected carcinoma are grouped together into one category of "noninvasive high grade neoplasia," similar to the suggestion of the current study. The usefulness and reproducibility of such new terminology will need to be evaluated further.

In conclusion, the results of the current study show that large differences currently exist between Western and Japanese pathologists with regard to how they diagnose squamous dysplasia and squamous cell carcinoma of the esophagus, and that these differences can in large part be resolved by adopting diagnostic terminology based on the presence or absence of invasion. For both clinical and basic research purposes, it is essential that an acceptable uniform nomenclature of esophageal squamous neoplastic lesions be developed and adopted.

REFERENCES

1. Makuuchi H, Machimura T, Shimada H, Mizutani K, Chino O, Kise Y, et al. Endoscopic screening for esophageal cancer in 788 patients with head and neck cancers. *Tokai Exp Clin Med* 1996;21:139–45.
2. Lewin KJ, Riddell RH, Weinstein WM. Gastrointestinal pathology and its clinical implications. 1st edition. New York: Igaku-Shoin, 1992:442–68.
3. Yoshida S. Endoscopic diagnosis and treatment of early cancer in the alimentary tract. *Digestion* 1998;59:502–8.
4. Dawsey SM, Fleischer DE, Wang GQ, Zhou B, Kidwell JA, Lu N, et al. Mucosal iodine staining improves endoscopic visualization of squamous dysplasia and squamous cell carcinoma of the esophagus in Linxian, China. *Cancer* 1998;83:220–31.
5. Martin IG, Young S, Sue-Ling H, Johnston D. Delays in the diagnosis of oesophagogastric cancer: a consecutive case series. *BMJ* 1997;314:467–70.
6. Lambert R. Endoscopic treatment of esophagogastric tumors. *Endoscopy* 1996;28:27–37.
7. Makuuchi H, Machimura T, Mizutani K, Shimada H, Kanno K, Tajima T, et al. Controversy in the treatments for superficial esophageal carcinoma: indications and problems of the procedures. *J Jpn Surg Soc* 1992;93:1059–62.
8. Chino O, Makuuchi H, Machimura T, Mizutani K, Shimada H, Kanno K, et al. Treatment of esophageal cancer in patients over 80 years old. *Surg Today* 1997;27:9–16.
9. Kumagai Y, Makuuchi H, Mitomi T, Ohmori T. A new classification system for early carcinomas of the esophagus. *Dig Endosc* 1993;5:139–50.
10. Yoshinaka H, Shimazu H, Fukumoto T, Baba M. Superficial esophageal carcinoma: a clinicopathological review of 59 cases. *Am J Gastroenterol* 1991;86:1413–8.
11. Schmidt LW, Dean PJ, Wilson RT. Superficially invasive squamous cell carcinoma of the esophagus: a study of seven cases in Memphis, Tennessee. *Gastroenterology* 1986;91:1456–61.
12. Froelicher G, Miller G. The European experience with esophageal cancer limited to the mucosa and submucosa. *Gastrointest Endosc* 1986;32:88–90.
13. Bogomoletz WV, Molas G, Gayet B, Potet F. Superficial squamous cell carcinoma of the esophagus: a report of 76 cases and review of the literature. *Am J Surg Pathol* 1989;13:535–46.
14. Yokoyama A, Ohmori T, Makuuchi H, Maruyama K, Okuyama K, Takahashi H, et al. Successful screening for early esophageal cancer in alcoholics using endoscopy and mucosa iodine staining. *Cancer* 1995;76:928–34.
15. Lewin KJ, Appelman HD. Atlas of tumor pathology. Third series. Fascicle 18. Tumors of the esophagus and stomach. Washington, DC: Armed Forces Institute of Pathology, 1996:43–97.
16. Schlemper RJ, Itabashi M, Kato Y, Lewin KJ, Riddell RH, Shimoda T, et al. Differences in diagnostic criteria for gastric carcinoma between Japanese and Western pathologists. *Lancet* 1997;349:1725–9.
17. Schlemper RJ, Itabashi M, Kato Y, Lewin KJ, Riddell RH, Shimoda T, et al. Differences in the diagnostic criteria used by Japanese and Western pathologists to diagnose colorectal carcinoma. *Cancer* 1998;82:60–9.
18. Watanabe H, Jass JR, Sobin LH. Histological typing of oesophageal and gastric tumours. World Health Organization international histological classification of tumours. 2nd edition. Berlin: Springer-Verlag, 1990:17–8.
19. Japanese Society for Esophageal Diseases. Guide lines for the clinical and pathologic studies on carcinoma of the esophagus. 8th edition. Tokyo: Kanehara, 1992:31–58.
20. Kato Y, Yagasaki K, Yanagisawa A. Histological criteria for diagnosis of esophageal carcinoma and dysplasia, applied especially for micro-atypical lesions in the esophagus. *Stomach Intestine* 1985;20:1303–9.
21. Watanabe H, Tada T, Iwafuchi M, Ajioka Y, Motoyama T, Ishihara N, et al. Does esophageal dysplasia really exist? *Stomach Intestine* 1991;26:133–40.
22. Watanabe H, Nakagawa S, Endo Y, Nishikura K, Ajioka Y. The histological diagnosis of esophageal squamous intraepithelial carcinoma and dysplasia. *Stomach Intestine* 1995;30:417–30.
23. Watanabe H, Matsuda K. The histological diagnosis of esophageal dysplasia. *Stomach Intestine* 1996;31:705–61.

24. Itabashi M, Yanagisawa A, Takubo M, Watanabe H, Shimoda T, Umigami M, et al. Esophageal dysplasia: now, how to think about it? *Stomach Intestine* 1996;31:762–78.
25. Svanholm H, Starklint H, Gundersen HJG, Fabricius J, Barlebo H, Olsen S. Reproducibility of histomorphologic diagnoses with special reference to the kappa statistic. *APMIS* 1989;97:689–98.
26. Rosai J. Ackerman's surgical pathology. 8th edition. St. Louis: Mosby, 1996:1358–63.
27. Ishiguro S, Kasugai T, Hoshida Y, Miwa S, Onodera M. Follow-up study of esophageal dysplasia: its diagnosis and histological change. *Stomach Intestine* 1996;31:695–704.
28. Momma K, Yoshida M, Nakamura J, Yamada Y, Kato H, Hanashi T, et al. Endoscopic mucosal resection for mucosal cancer of the esophagus. *Clin Gastroenterol* 1997;12:1733–40.
29. Dawsey SM, Lewin KJ, Wang G-Q, Liu F-S, Nieberg RK, Yu Y, et al. Squamous esophageal histology and subsequent risk of squamous cell carcinoma of the esophagus: a prospective follow-up study from Linxian, China. *Cancer* 1994;74:1686–92.
30. Takeshita K, Tani M, Inoue H, Saeki I, Hayashi S, Honda T, et al. Endoscopic treatment of early oesophageal or gastric cancer. *Gut* 1997;40:123–7.
31. Meyer V, Burtin P, Bour B, Blanchi A, Cales P, Oberti F, et al. Endoscopic detection of early esophageal cancer in a high-risk population: does Lugol staining improve videoendoscopy? *Gastrointest Endosc* 1997;45:480–4.
32. Schlemper RJ, Iwashita A, Itabashi M, Kato Y, Shimoda T, Watanabe H, et al. Well-differentiated adenocarcinoma or dysplasia of the gastric epithelium: results of international comparative studies. *Pathol Res Pract* 1999;195:307.
33. Schlemper RJ, Riddell RH, Kato Y, Borchard F, Cooper HS, Dawsey SM, et al. The Vienna classification of gastrointestinal epithelial neoplasia. *Gut* 2000;46. In press.